



STUDIES ON SOME INTERNAL PARASITES OF GOATS IN ASSIUT GOVERNORATE ESPECIALLY WHICH AFFECTING LIVER

Mohsen. I. Arafa and Ibrahim. A. Fouad

Animal Health Research Institute, Assiut Laboratory

ABSTRACT:

This study was carried out throughout one year from January 2006 to December 2006 at Assiut Governorate, to determine some epidemiological features concerning parasitic infection of goats. Out of 350 faecal samples of goats were examined, 321 animals proved to be infected with different internal parasites, representing an incidence rate of 91.7%. The total infection rate of *Eimeria* was 88.9% and the total infection rate of different helminthes was 25.4%. Infection rate in kids was 97.4% and in adults was 87.3%. The infection rate of the nematode worms was 22.0%, *Trichostrongylus sp.* showed high rate of infection (6.3%) while *Capillaria sp.* was the lowest one (0.3%). *Moniezia sp.* eggs were detected in 2.9% of examined goats. Trematode infection represented as *Fasciola* and *Paramphistomum* eggs were detected in 3.4% and 0.9% respectively.

Study the effect of seasonal variation clear that the highest infection rate of *Eimeria* was detected in summer season (93.8%) while the highest infection rate of most helminthes was detected in spring and winter seasons.

For studying the parasitic infection of goat's liver, 350 slaughtered goats were examined. Forty eight (13.7%) cases showed parasitic infection in their liver. Macroscopic examination of goat's liver showed *Fasciola gigantica* and *Cysticercus tenuicollis* in 6.28% 6.86% respectively. Histopathological examination of liver tissues revealed presence for the first time at Assiut Governorate, *Eimeria* infection and ascarid sp. larvae in 0.3% of examined cases. Both eimerian oocysts and ascarid larvae were detected in artificial digested livers. Histopathological sections of infected liver with *Eimeria* revealed presence of portal and peri-portal inflammatory cell reactions, necrobiotic changes of hepatocytes and biliary epithelial hypertrophy and hyperplasia. In case of infection with *Ascaris* larvae, liver showed presence of multiple parasitic granulomas containing sections of larvae.

INTRODUCTION:

Goats play an important role in providing animal protein for the diet, especially for these people who live in the villages in addition to cashmere and mohair fibers production (Smith and Sherman, 1994).

Under arid conditions especially when accompanied with unsuitable hygienic

measurements goats become susceptible to various parasitic infections. The parasitic diseases are sometimes so serious causing great economic losses and their mortality rate may be reach to 30- 40% (Soulsby, 1965).

The goats also serves as an intermediate host for a number of cestode parasites that used canids as definitive host as *Echinococcus granulosus*, *Taenia hydatigena* and *Taenia ovis*.

These infection are more economically and clinically significant than the adult tapeworm infections (Smith and Sherman, 1994).

However, little studies are available on the internal parasites of goats especially in Upper Egypt.

Therefore, the present work was planned to study the prevalence of different parasites infect goats in Assiut Governorate and the relationship between them. In addition to explore the pathological alterations in some infected livers of examined goats.

MATERIALS AND METHODS:

1-Collection and examination of fecal samples:

Three hundred and fifty rectal fecal samples were collected from apparently healthy goats (153 less than six months and 197 more than six months) from different localities in Assiut Governorate during January 2006 to December 2006. Each sample was collected in clean plastic cup and delivered directly to the laboratory for examination.

- Fecal samples were examined for the presence of diagnostic parasitic stages by both the centrifugation floatation using saturated sodium chloride solution and sedimentation techniques (Abdel-Gawad 1972).
- Fecal culture was performed for identification of stongyloride larvae according to Eckert (1960).
- Identification of the collected eggs and larvae was done according to Dunn (1978) and Soulsby (1982).
- The percentage of infection, age and seasonal variations of each species were determined.

2-Gross and histopathological examinations of liver:

- A total of 350 adult goats were slaughtered in different Assiut abattoirs, their livers and corresponding bile ducts were macroscopically examined carefully for parasitic infection.
- Interesting samples of the liver tissue were divided into two parts; one half was fixed in 10% neutral buffered formalin. Fixed tissues were processed routinely for paraffin embedded technique, sectioned at 4 um and stained with hematoxylin and eosin (H&E) according to Bancroft and Stevens (1982). Other half was digested in artificial gastric juice for isolation of oocysts and larvae distributed in the liver tissues according to Bhopale and Johri (1975).

RESULTS AND DISCUSSION:

1 -Frequency of occurrence:

Out of the 350 goat fecal samples were examined in the present survey, only 29 goats were parasitic negative, the remaining 91.7% were positive at least by one type of parasitic infection.

Eimeria infection was the most prevalent parasitic infection (88.9%) in surveyed goats; their infection rate was 96.4% in kids and 87.3% in adults. High incidence is the common phenomena of *Eimeria*; Norton, (1986) detected it in 98% of goats at England, Ocallaghan, (1989) at South Australia recorded it in 97%, and Alyousif *et al.*, (1992) detected it in 90.3% at Saudi Arabia. In Egypt Otify (1984) and Arafa (2001) detected it in 94.65% and 93.25% of examined goats respectively. Smith and Sherman (1994) mentioned that *Eimeria* oocysts

are widely present in faeces of both normal and diseased goats with reported range of 38% to 100% of all goats. They attributed the high incidence of *Eimeria* to the quite resistance of their oocysts to the environmental degradation and exposure of animals to poor hygienic conditions.

Concerning to helminthes infection in the present work, they were detected in 25.4% of examined goats, where the infection rate was 32.0% in adults and 17.0% in kids (Table 1).

Most cases of helminthes infection in the present work were mixed with *Eimeria* infection 22.57% (Table1). Kanyari (1993) mentioned

that there is a positive correlation between *Eimeria* and helminthes infection in examined sheep and goats, this related to the role of contamination in the acquisition of both types of infection.

Fourteen genera of helminthes were detected in examined goats listed in tables 2 & 3. Infection with *Cooperia*, *Skarbojenema* and *Paramphestomum* had not previously been reported in goats in Assiut Governorate. The incidence of most detected helminthes observed in the present work was lower in kids than adults. Infection with *Fasciola*, *Ostertagia* and *Capillaria* were detected in adults only.

Table (1): Prevalence of parasitic infection in examined goats in Assiut Governorate

Animals	Ex. animals	Inf. animals		Single coccidia		Single helminthes		Mixed infection		Total coccidia		Total helminthes	
		No.	%	No.	%	No.	%	No.	%	No	%	No	%
Kids	153	149	97.4	123	80.4	2	1.3	24	15.7	147	96.1	26	17.0
Adults	197	172	87.3	109	55.3	8	4.1	55	27.9	164	83.2	63	32.0
Total	350	321	91.7	232	66.3	10	2.9	79	22.57	311	88.9	89	25.4

Table (2): Prevalence of different parasites in examined goat at Assiut Governorate

Parasitic species	Kids (N=153)		Adults (N=197)		Total (N=350)	
	No.	%	No.	%	No.	%
Nematode:	24	15.7	53	26.9	77	22.0
<i>Trichuris ovis</i>	6	3.9	9	4.6	15	4.3
Stongyloride like eggs	18	11.8	49	24.9	67	19.1
<i>Skarbojenema sp.</i>	1	0.65	3	1.5	4	1.1
<i>Toxocara vitulorum</i>	1	0.65	1	0.5	2	0.6
<i>Capillaria sp.</i>	-	-	1	0.5	1	0.3
Cestode (<i>Monezia Sp.</i>)	3	1.96	7	3.55	10	2.9
Trematode:	1	0.65	12	6.1	13	3.7
<i>Fasciola Sp.</i>	-	-	12	6.1	12	3.4
<i>Paramphestomum Sp.</i>	1	0.65	2	1.0	3	0.9
Protozoa (<i>Eimeria sp.</i>)	147	96.1	164	83.2	311	88.9

Table (3): Prevalence of helminthes detected by faecal culture in examined goats

Parasitic species	Kids (N=153)		Adults (N=197)		Total (N=350)		The characteristic points of their infective larvae
	No.	%	No.	%	No.	%	
<i>Trichostrongylus sp.</i>	5	3.3	17	8.6	22	6.3	Short straight larva end with small tubercle, conical tail sheath.
<i>Bunostomum sp.</i>	3	3.3	11	5.6	14	4.0	Wide body with sudden tapering to thin long tail.
<i>Oesophagostomum sp.</i>	4	2.6	11	5.6	15	4.3	Simple pointed long tail.
<i>Chabertia sp.</i>	1	0.65	8	4.1	9	2.6	Stout body larva and it has 32 rectangular intestinal cells
<i>Haemonchus sp.</i>	1	0.65	7	3.55	8	2.3	Head bullet-shaped, and had pointed tail of larva.
<i>Ostertagia sp.</i>	-	-	7	3.55	7	2.0	Conical, finger like tail.
<i>Cooperia Sp.</i>	6	3.9	3	1.5	9	2.6	Two conspicuous oval bodies at anterior end of oesophagus

Regarding to nematode infection, they were detected in 22.0% of examined goats. The most predominant nematodes in examined faecal samples were *Strongyloride*- like eggs (19.1%) while in faecal culture the predominant worms were *Trichostrongylus sp.*, *Oesophagostomum sp.* and *Bunostomum sp.*, their infection rates were 6.3%, 4.3% & 4.0% respectively (Tables 2 & 3 Plate I).

The percentages of nematode infections in the present work were lower than that mentioned by Monib (1977) who recorded the percentage of: *Trichuris*, *Haemonchus* and *Oesophagostomum*, as 77.6%, 14.4% and 7.2%, respectively. While the obtained results is higher when compared with that recoded by Ahmed (1998) who reported that nematode infection rate in goats at Assiut and Sohag Governorates was 9.2% and he added also that *Trichostrongylus sp.* was the most common nematode (2.6%). This difference mostly attributed to several factors as breeding system of examined animals, phase of infection during the examination or laboratory techniques used in examination of samples.

Concerning to trematode infection, their total infection rate was 3.7%. *Fasciola* eggs were

detected only in adult goats and their rate was 6.1%. The obtained result agreed with Haridy *et al.*, (1990) and Sobhy (2004) they detected *Fasciola* in goats at 3.54% and 3.41% respectively. Absence of *Fasciola* infection in kids in the present work agree with the same result of El- Sherif & Abo-El-Hadid (2005) they mentioned that fascioliasis infection began to appear at five to six months of age. Infection with *Paramphestomum sp.* detected in both kids and adults, their rates were 0.65% and 1.0%. Cestode infection represented as *Moniezia sp.* was detected in 2.9% of examined goats (Table 2). *Moniezia* infection was detected previously in goats by Monib (1977) while *Paramphestomum* infection had not detected previously.

Regarding to the effect of seasonal variation on the incidence of parasitic infection were listed in table (4); *Eimeria* infection was high allover the year especially in summer season, it was ranged from 83.7% in autumn to 93.8% in summer. This result agreed with Harper and Penzhorn (1999) they found a significant increase in infection rate of *Eimeria* during dry season. Smith and Sherman (1994) mentioned that hot and humid weather is particularly conducive to sporocyst

development and outbreaks of clinical coccidiosis are common during summer, especially spring-born kids are being weaned during the hot, humid months.

Regarding to the seasonal distribution of nematodes in the present work noticed that: incidence of most nematodes (strongyloride) increased gradually at autumn and reached to the peak of infection either in winter or spring. A pronounced decline in infection rate was usual seen in summer. This pattern of infection of strongyloride may relate to the spring rise phenomena in addition to the infective stages of most strongyloride worms not resist the hot dry weather. Soulsby (1965) and Herd (1971) mentioned that: end of winter and beginning of spring is considered as the peak of reproduction of most strongyloride worms. They added also, maturation of their inhibited larvae takes place

in spring season which known as spring rise. Vice-versa, peak of infection of *Trichuris ovis* was detected in summer; this may related to their infective stage is more resist the hot dry season as a result of their thick shell. Infection rate of *Fasciola sp.* in the present work was relatively similar at each season. This may be related to long life- span of this parasite, extensive movement of goats and irrigation by flooding. Concerning to *Moniezia sp.* the maximum of their infection rate was detected in autumn, which may followed the activity of their intermediate host (Oribatid mites). Hassaein (1978) mentioned that the highest activity of Oribatid mites was seen in summer season. Low level of other helminthes (*Capillaria*, *Toxocara vitulorum* and *Paramphestomum*) not help to study their seasonal distributions.

Table (4): Seasonal variations of different parasites in examined goats at Assiut

Parasitic species	Summer (N= 97)		Autumn (N=86)		Winter (N=82)		Spring (N=85)	
	No.	%	No.	%	No.	%	No.	%
<i>Trichuris ovis</i>	6	6.2	3	3.5	3	3.7	3	3.5
<i>Trichostrongylus sp.</i>	2	2.1	9	10.5	-	-	11	12.9
<i>Cooperia Sp.</i>	3	3.1	2	2.3	1	1.2	3	3.5
<i>Bunostomum sp.</i>	2	2.1	3	3.5	4	4.9	5	5.9
<i>Oesophagostomum sp.</i>	-	-	5	5.8	6	7.3	4	4.7
<i>Chabertia sp.</i>	-	-	2	2.3	2	2.4	5	5.9
<i>Haemonchus sp.</i>	1	1.0	2	2.3	4	4.9	1	1.2
<i>Ostertagia sp.</i>	-	-	-	-	4	4.9	3	3.5
<i>Skarbojenema sp.</i>	1	1.0	1	1.2	1	1.2	1	1.2
<i>Toxocara vitulorum</i>	-	-	1	1.2	-	-	1	1.2
<i>Capillaria sp.</i>	1	1.0	-	-	-	-	-	-
<i>Monezia Sp.</i>	4	4.1	5	5.8	2	2.4	-	-
<i>Fasciola Sp.</i>	3	3.1	3	3.5	3	3.7	3	3.5
<i>Paramphestomum</i>	-	-	-	-	-	-	3	3.5
<i>Eimeria Sp.</i>	91	93.8	72	83.7	72	87.8	76	89.4

2-Liver examination:

Gross post-mortem examination of 350 slaughtered goats revealed the presence of: *Fasciola* infections in 6.28% and *Cysticercus tenuicollis* in 6.86%. Histopathological examination of liver tissues revealed presence of *Ascarid sp.* larvae in 0.3% and *Eimeria* infection in 0.3% (Table 5).

A- *Fasciola* infection:

Fasciola sp. that detected in present study was only *F. gigantica* depending upon morphological criteria of the adult flukes. The obtained result similar with the pervious studies at Assiut Governorate by: Monib (1977) and Ali (2001), they recorded that the infection rate of fascioliasis in slaughtered goats was 6.4% and 11.6% respectively.

In the present work the incidence of *Fasciola* in slaughtered goats not coincided with those found in faecal examination of living once. This difference may be interpreted to the low number and irregular pattern of egg production in addition to the pathological changes in the affected liver, in addition to all slaughtered goats were more than 8 months. The same difference was detected by Abdel-Aal *et al.* (1999) in examined goats at Ismailia province.

B-*Cysticercus tenuicollis*:

The recovered cysts were either embedded in the hepatic tissues or attached to the liver surface with long neck. They were variable in

size measured 1.5-3.0x1.0-2.5 cm (2.0x1.5 cm). Most of detected cysts were transparent grayish white in colour, they had a thin wall through which a single scolex appeared as a white spot (plate II Fig. 1).

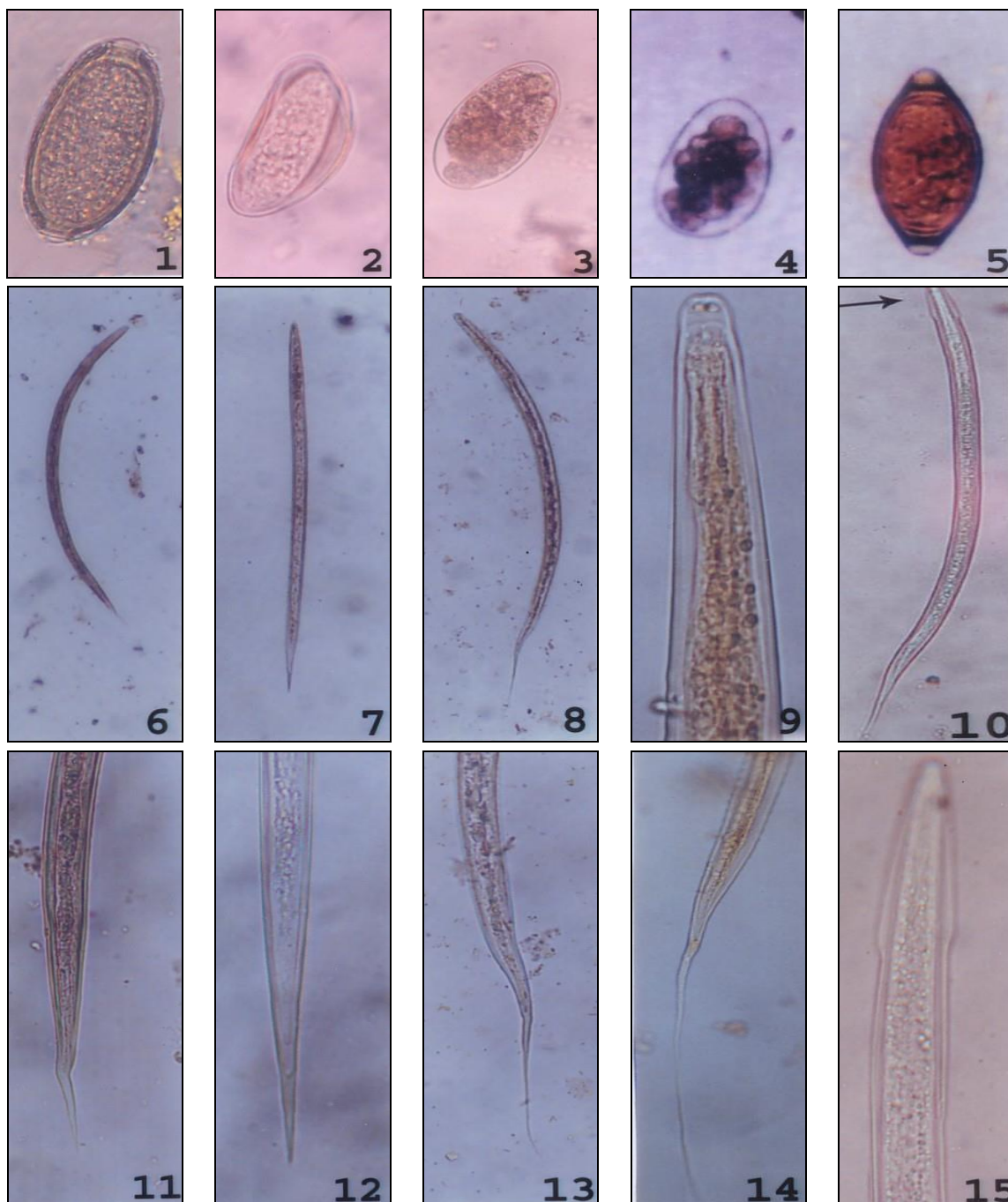
The incidence of *C. tenuicollis* in the present work was relatively coinciding with that obtained by Ali (2001) in Assiut Governorate but it was lower than that recorded by Fathi and Abel Haseeb (2006) they detected it in 19% of examined goats in Libya. This difference may attribute to high populations of stray dogs and other wild carnivores in desert regions of Libya which play an important role in infection with *C. tenuicollis*.

C-*Eimerian* infection:

It was detected in one goat; the liver was enlarged and had multiple firm gray-white patches. These patches had tortuous shape. Cut sections in these patches revealed enlarged easily recognizable proliferated bile ducts. Microscopical examination of their content revealed presence of small spherical eimerian oocysts identified as *Eimeria alijeivi* depending upon their measurements (16.3x13.6µm) and morphological characters (Plate II Fig. 2). It is the first time for detection of hepato-biliary coccidiosis in goats at Assiut Governorate. Several species of *Eimeria* (*E. alijeivi*, *E. caprina* and *E. ninakohlykimovae*) were detected in liver of goats previously by; Dia *et al.* (1991) and Mahmoud *et al.* (1994).

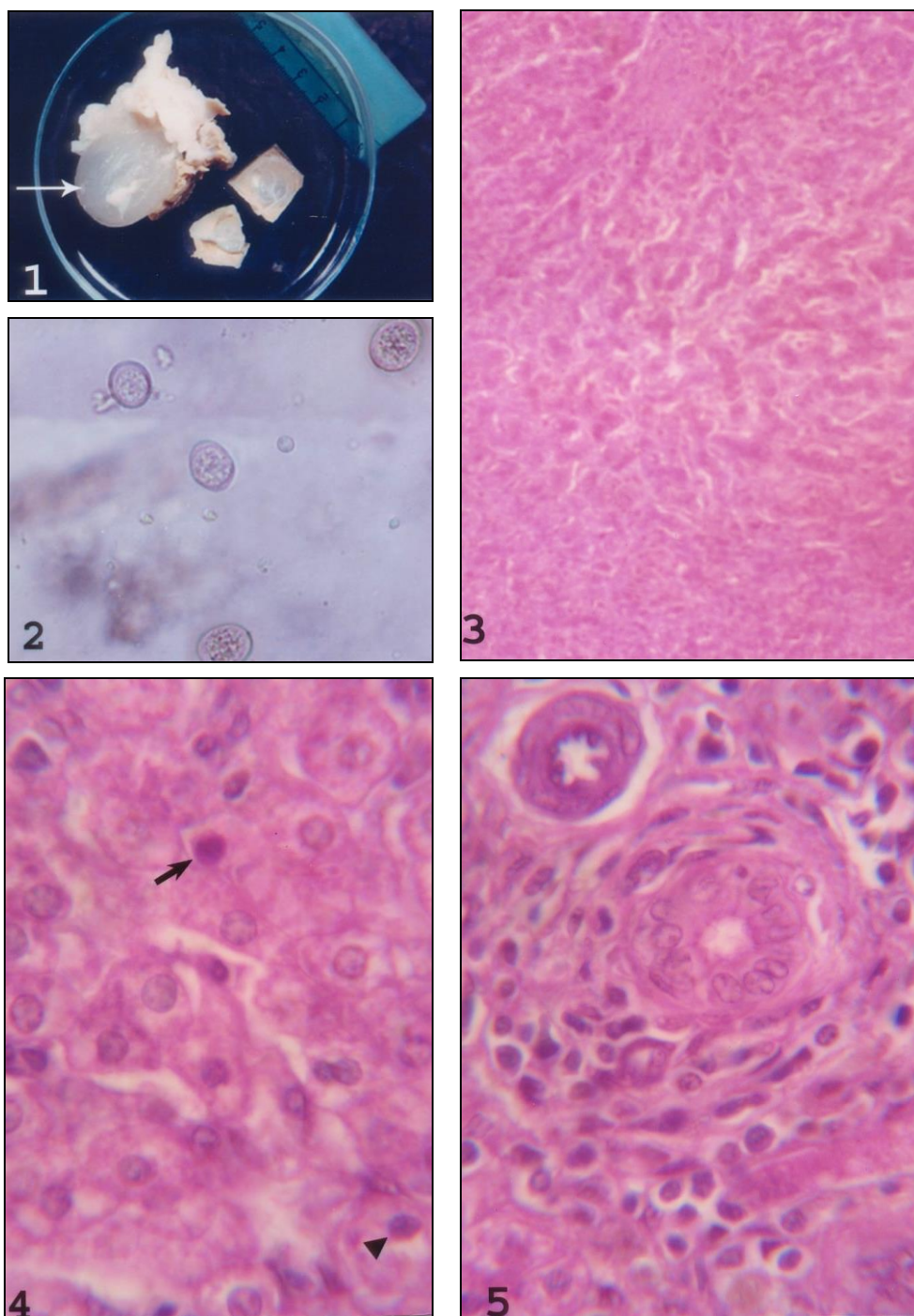
Table (5): Incidence of various Parasitic infection in liver of examined goats (350 cases)

Infected Animals	<i>Fasciola</i> infection	<i>Cysticercus Tinencoulus</i>	<i>Eimeria</i> infection	<i>Ascarid</i> larvae
(N) 48	22	24	1	1
(%) 13.7	6.28	6.86	0.3	0.3



(Plate I): Figures of some nematode eggs and larvae of examined goats

- | | |
|---|---|
| (1) <i>Capillaria sp.</i> egg. | (2) <i>Skarbojenema sp.</i> egg. |
| (3&4) Strongyloride eggs. | (5) <i>Trichuris sp.</i> egg. |
| (6) 3 rd stage larva of <i>Ostertagia sp.</i> X 40. | (7) 3 rd stage larva of <i>Trichostrongylus sp.</i> X 40. |
| (8) 3 rd stage larva of <i>Chabertia sp.</i> X 40. | (9) Anterior end of 3 rd stage larva of <i>Cooperia sp.</i> X 100. |
| (10) 3 rd stage larvae of <i>Haemonchus sp.</i> , note bullet -shaped head (arrow) X 40. | |
| (11) Posterior end of 3 rd stage larva of <i>Ostertagia sp.</i> X 100. | |
| (12) Posterior end of 3 rd stage larva of <i>Trichostrongylus sp.</i> X100. | |
| (13) Posterior end of 3 rd stage larva of <i>Chabertia sp.</i> X100. | |
| (14) Posterior end of 3 rd stage larva of <i>sp. Cooperia sp.</i> X 100. | |
| (15) Anterior end of 3 rd stage larvae of <i>Haemonchus sp.</i> X 100. | |



(Plate II)

Fig. (1): Variable size of detected *Cysticercus tenuicollis* in examined goats, note scolex as white spot (arrow).

Fig. (2): Coccidian oocysts detected in content of bile ducts X 100.

Fig. (3): Periportal area showing disruption of hepatic cords caused by fibrous connective tissue proliferations. H& E X 200.

Fig. (4): Liver of a goat showing necrobiotic changes of hepatocytes. Note the presence of coccidian macrogamonts (arrow) and microgamonts (arrow heads) in hepatic sinusoids. H&E X 320.

Fig. (5): Periportal area showing hypertrophy of biliary epithelium and inflammatory cell reactions composed of macrophages, lymphocytes, eosinophils and fibrocytes. H&E X 320.

The gross features which detected in present work were similar among reported cases of hepatic coccidiosis in rabbits, mink and goats (Grafiner *et al.*, 1967, Levine, 1985, Dubey, 1986 and Yabin *et al.*, 1991). In contrast, in a calf with hepatic coccidiosis, liver was enlarged but bile ducts were not sufficiently enlarged to be grossly recognizable (Collins *et al.*, 1988).

Histopathological examination of affected liver revealed that: portal and peri-portal areas contained much fibrous connective tissue and inflammatory cell reactions composed of macrophages, lymphocytes and eosinophils (plate II Figs. 3-5). The hepatic cords were disrupted and hepatocytes especially in peri-portal areas showed necrobiotic changes (plate II Figs. 3-5). Many intrahepatic bile ducts had uneven luminal surface and were lined by tall columnar epithelium with enlarged nuclei and nucleoli, indicating hypertrophy and hyperplasia (Plate III Figs. 1&2). Different stages of coccidian included meronts, macrogamonts and microgamonts were encountered intracytoplasmic in epithelial cells of hyperplastic bile ducts (Plate III Figs 1,2 &3). Four or more merozoites were observed in each meronts (Plate III Fig. 2). Macrogamonts and microgamonts were occasionally observed free in portal areas or in hepatic sinusoids (plate III Fig. 3). Oocysts could be observed with cell debris and sloughed epithelial cells in lumen of bile ducts (plate III Fig. 1).

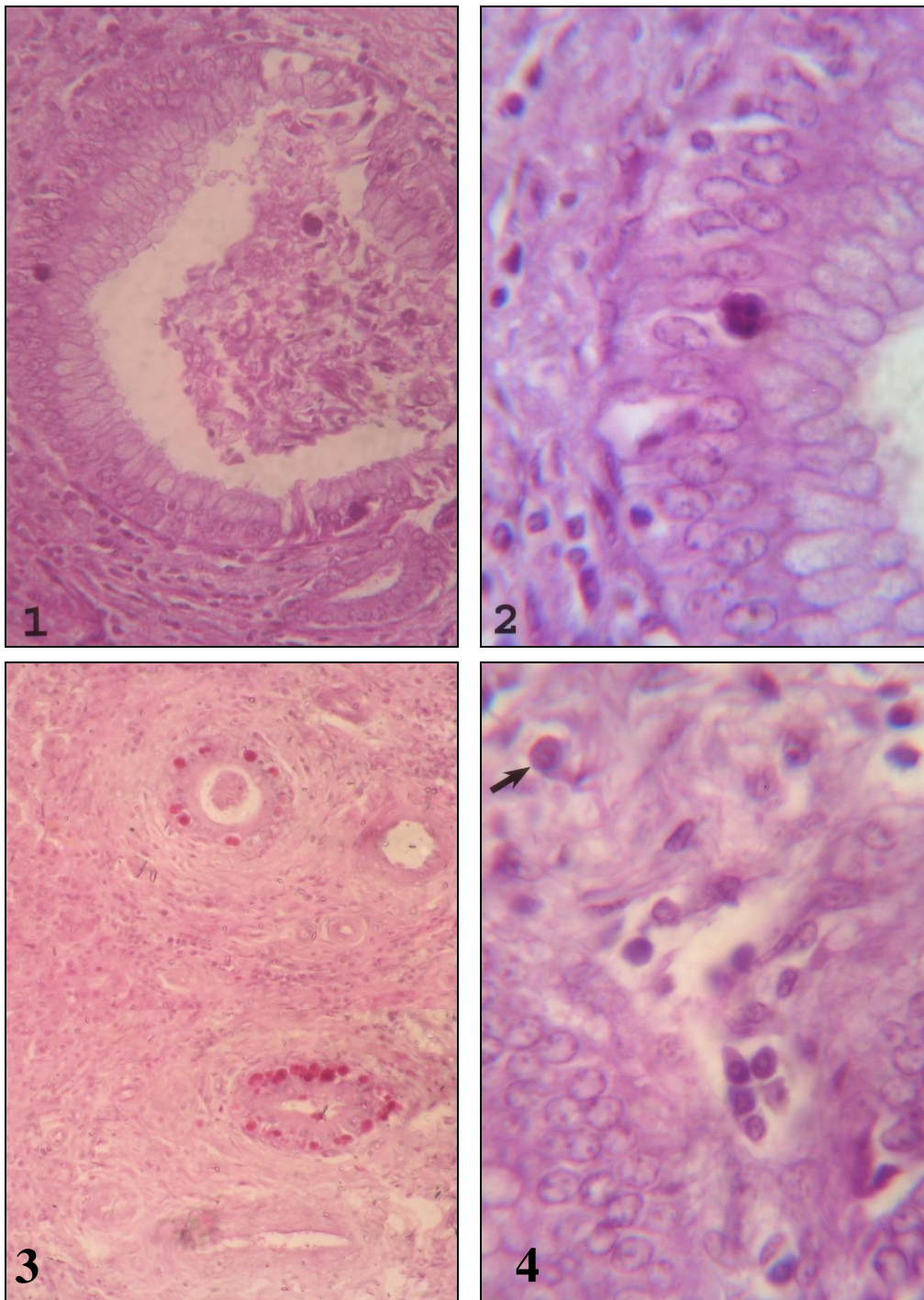
These inflammatory reactions encountered nearby the parasitized bile ducts and necrobiotic changes of hepatocytes may attribute to direct or indirect action of coccidian organisms. The later opinion had been previously considered by Schafer *et al.* (1995) who attributed the presence of hepatic necrosis in hepatic coccidiosis of goats to one or more stages of coccidian organisms either directly or indirectly.

As a rule, a potential route of hepatic infection with coccidian is ascending infection from the intestine via bile ducts or via lymphatic (Lindsay *et al.*, 1990 & Schafer *et al.*, 1995). Limited researches indicated that coccidia may be transported in the circulation within macrophages (Schafer *et al.*, 1995). In the present study, the presence of macrogamonts and microgamonts in hepatic sinusoids may indicate the haemato- genic route.

D-Ascarid larvae:

In another goat, the liver had pale spots (0.5 cm. in diameter). These spots had normal consistency and extended shortly in hepatic parenchyma. Highly granulated rhabditiform larvae were recovered by microscopical examination of the artificial digested liver tissues, their measurements were 270-350 x16.5-18.8 μm (plate IV Fig. 1). The morphological criteria of the detected larvae were coincided with that of second stage larvae of ascarid worms. Smyth (1994) mentioned that *Ascaris* larvae appear as second stage larvae in the liver within six hours post-infection and remain in the liver for a few days and then develop to the early third stage larvae. Isolation of *Toxocara vitulorum* larvae from liver and other internal organs of experimentally infected chickens by artificial digested juice was previously done by Sabry (2001).

Histopathological examination of the affected tissue revealed the presence of parasitic granulomas. Each of them composed of a necrotic core containing a cross section in the larva and surrounded by aggregations of lymphocytes, macrophages and eosinophils (plate IV Fig. 2). These granulomas were demarcated by fibrous capsule (plate IV Fig. 2). The hepatocytes were more or less unchanged. A part of the larva was observed in close contact with arterial intima (plate IV Fig. 3).



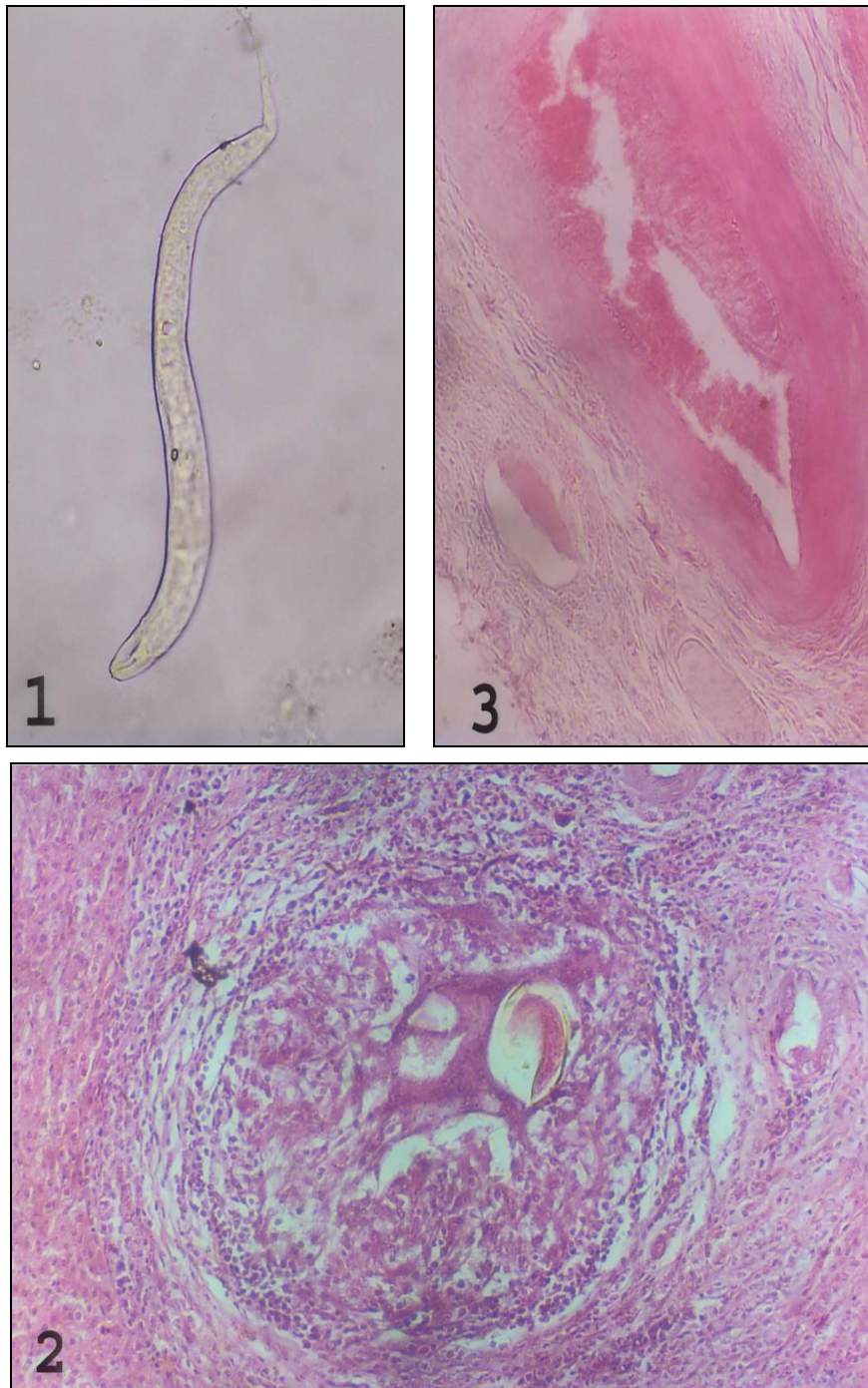
(Plate III)

Fig. (1): Periportal area showing hyperplasia of a bile duct epithelium with presence of intra-cytoplasmic coccidian meronts. The lumen of bile duct contains oocysts and cellular debris. H&E X 200.

Fig. (2): Higher magnification of the Fig. (1), showing presence of four merozoites within the coccidian meront H&E X 800.

Fig. (3): Liver of a goat showing presence of different stages of coccidian in epithelial cells of bile ducts H&E X 200

Fig. (4): Periportal area showing hyperplasia of a bile duct epithelium, mononuclear cell reactions and presence of microgamonts (arrow). H&E X 320.



(Plate IV)

Fig. (1): *Ascarid* second stage larvae detected in digested liver of infected goat X 80.

Fig. (2): Liver of a goat showing presence of a parasitic granuloma composed of necrotic core containing a longitudinal section in the larva and surrounded by lymphocytes, macrophages, eosinophils and a fibrous capsule. H&E X 320.

Fig. (3): Periportal area showing presence of larva in- close contact with arterial intima H&E X 200.

Migration of nematode larvae through the internal organs especially the liver and lungs is a common occurrence in domestic animals (John *et al.*, 2001). Infective ascarids larvae penetrate the intestinal wall and migrate to the liver via the portal circulation (John *et al.*, 2001). Presence of the detected larvae in a portal blood vessel in a goat in the present study was agreed with the last postulation. The composition of the hepatic granulomas in the present study was similar to granulomas elicited by nematode larvae or its eggs (Ibrahim *et al.*, 1989. Palmer *et al.*, 1998 and John *et al.*, 2001). Multiple parasitic granulomas detected in the present case caused by ascarid larvae indicated high response of goat's liver as a migration route for *Ascaris* larvae.

Results of the present work proved that goats play a very important role in dissemination of internal parasites between different animals. Dangerous of this role increase by the fact that the examined goats were apparently healthy.

REFERENCES:

- Abdel-Aal, A.A., Aboou-Eisha, A.M. and El-Sheary, M.N.(1999): Prevalence of fascioliasis among man and animals in Ismailia Province. *Assiut Vet. Med. J.* 41 (81) 141-152.
- Abdel-Gawad, A.F.(1972): Differential diagnosis of gastro-intestinal strongylosis of sheep in Egypt through the free living stage larvae. 10 th. Arab. Vet. Congress 12-19 Feb. pp. 212-227.
- Ahmed, A. El-Badry (1998): Studies on Gastroenteritis caused by nematodes of goats in Upper Egypt using some drugs for treatment. Ph. D. Animal Medicine. Fac. Vet. Med. Assiut Univ. .
- Ali, S.F. (2001): Morphopathological studies on some liver affections of goats in Assiut Governorate with special reference to parasitic lesions. M.V. Sc. Vet. Path. Fac. Vet. Med. Assiut University.
- Alyousif, M.S., Kasim, A.A. and Shawa, Y.R. (1992): Coccidiosis in domestic goats (*Cabra hircus*) in Saudia Arabia. *Inter. J. Parasitol.* 22(6) 807-811.
- Arafa, M.I. (2001): Prevalence study on coccidian of goats in Assiut Governorate with notes on seasonal Variation. *Assiut Vet. Med. J.* 46:(92) 213- 223.
- Bancroft, J.D. and Stevens, A. (1982):“Theory and practic of Histologic Techniques.” 3 rd. Ed. Long Man Group Limited
- Bhopale, M.K. and Johri, G.N.(1975): Experimental infection of *Ancylostoma caninum* in mice. II Migration and distribution of larvae in tissues after oral infection. *J. Helmenth*, 49:179-185.
- Collins. J.E., Dubey, J.P. and Rossow, K.D. (1988): Hepatic coccidiosis in a calf. *Vet. Path.* 25: 98-100.
- Dia, Y.B., Lin, M.C., Zhang, S. X. and Fu, A.Q. (1991): Hepatic coccidiosis in the goat. *Int. J. Parasitol.* 21 (30):381-382.
- Dubey, J.P. (1986): Coccidiosis in the gallbladder of a goat. *Proc. Helminthol. Soc. Wash.* 53: 277-281.
- Dunn, A. M. (1978): *Veterinary Helminthology.* 2nd Ed. Bulter & Tanner Lid, Frome and Landon. Pp.295-304.
- Eckert, J. (1960): The diagnosis of gastro-strongylosis in sheep by differentiation of the free-living third stage larvae. *Zentralblatt fur. Vet. Med.*, 94:612-629.
- El-Sherif, A.M. and Abo-El-Hadid, S.M. (2005): Epizootiological investigation about different internal parasitic affections among

- cattle calves in Beni-Suef Governorate. J. Egypt. Vet. Med. Asso. 65 (6) 261-274.
- Fathi, M.N. and Abdel Haseeb, S.N. (2006): Incidence and hazardous effect of some parasitic infestation of sheep and goats slaughtered at Al-Niqat Al Kams Province. 12 Sci. Cong. Fac. Vet. Med. Assiut Univ. Egypt. 199- 215.
- Grafiner, G., Graubmann, H.D. and Dobbriner. W. (1967): Hepatic coccidiosis in mink (*Lutreola vison Schreb*) caused by a newly identified species of coccidian *Eimeria hiepei n. sp.* Monatsschrey Veterinaermed. 22: 696-700.
- Harper, C.K. and Penzhorn, B.L. (1999): Occurrence and diversity of coccidian in indigenous, Saanen and crossbred goats in South Africa. Vet. Parasitol., 82(1):1-9.
- Haridy, F. M., Ibrahim, B. B., Morsy, T. A. and Sharkawy, I. M. A.(1999): Fascioliasis an increasing zoonotic disease in Egypt. J. Egypt. Soc. Parasitol. 29 (1) 35-48.
- Hassaein, M.A. (1978): Morphological and biological studies on tape-worms infesting sheep under the Egyptian environmental condition. M. V. Sc. Fac. Vet. Med. Cairo Univ.
- Herd, R.P. (1971): The parasitic life cycle of *Chabertia ovina* in sheep. Internat. J. Parasit. 1, 189-199.
- Ibrahim, M.K., Mahmoud, A.Z. and Khalifa, R. (1989): Pathological studies on parasitic hepatitis in goats. Egypt. J. Comp. Path. Clinical Path. II: (1) 47-55.
- John, M., Cullen, N. and James, M. (2001): Liver, Biliary system and exocrine pancreas in Thomson's special veterinary pathology 3 ed. Mosby, Inc. P 81-124.
- Kanyari, P.W. (1993): The relationship between coccidial helminth infections in sheep and goats in Kenya. Vet. Parasitol. 511-2:137-141.
- Levine, N.D. (1985): "Apicomplexa: *Sarcocystis*, *Toxoplasma* and related Protozoa" In Veterinary Protozoology 1 st ed. Vol CRC Press, Boca Raaton, Florida, USA. 233-240.
- Lindsay, D.S., Dubey, J.P. and Fayer R. (1990): Extraintestinal stages of *Eimeria bovis* in calves and attempts to induce relapse of clinical disease. Vet. Parasitol. 36:1-9.
- Mahmoud, O.M., Haroun, E.M. and Sulman, A. (1994): Hepato- biliary coccidiosis in a dairy goat. Vet. Parasitol. 53: 15-21.
- Monib, M. (1977): Study on some helminth parasites of ruminants in Assiut Governorate. M.Sc. Thesis. Fac. Vet. Med. Assiut Univ.
- Norton, C.C. (1986): Coccidia of the domestic goat (*Copra Hircus*), with notes on *Eimeria ovinoidalis* and *E. bakuensis* from sheep (*Ovis aries*). Parasitol., 92:279-289.
- Ocallaghan, M.G. (1989): Coccidia of domestic and feral goats in South Australia. Vet. Parasitol. 30 (4): 267-272.
- Otify, Y.Z.(1984): Studies on coccidian parasites of goats. Ph. D. Fac. Vet. Med. Alix. Univ.
- Palmer, S.R., Lord Soulsby and Simpson, D.I. N.H. (1998): Zoonose, biology, clinical practice and public health control. Oxford Newyork Tokyo, Oxford Univ. .
- Sabry, M.H.(2001): Chicken as a paratenic host for zoonotic *Toxocara vitulorum*. J. Egyp. Vet. Med. Ass. 61 (6) 195-206.
- Schafer, K.A., Stevenson, G.W. and Kazacos, K.R.(1995):Hepatic coccidiosis associated with hepatic necrosis in a goat. Vet. Path. 32:723-727.
- Smith, M. C. and Sherman, D.M. (1994): Goat Medicine. 1st Ed. Lea & Febiger U.S.A. Pp. 312-340.

Smyth, J.D. (1994): Introduction to animal parasitology. 3rd Ed. Cambridge Univ. press. Great Britain. Pp. 400-407.

Sobhy, F.S. (2004): Studies on caprine fascioliasis at Sohag Governorate. M. Sc. Fac. Vet. Med. Assiut Univ.

Soulsby, E.J.L. (1965): Textbook of veterinary clinical parasitology, Vol. 1 Helminths. Blackwell Scientific Publications, Oxford.

Soulsby, E.J.L.(1982): "Helminths, Arthropods and Protozoa of domestic animals."7th Ed. The English Language Book Society and Baillière Tindall, London. Pp. 795-803.

Yabin, D., Menchu, L., Shenxing, A.Z. and Aofi, F. (1991): Hepatic coccidiosis in the goat. Int. J. Parasitol. 21: 381-382.

دراسات على بعض الطفيليات الداخلية في الماعز بمحافظة أسيوط وخاصة التي تصيب الكبد.

محسن إبراهيم عرفة، إبراهيم أحمد فؤاد عبد الرازق

معهد بحوث صحة الحيوان بأسيوط

لدراسة مدى إنتشار الطفيليات الداخلية في الماعز بمحافظة أسيوط تم فحص عدد ٣٥٠ عينة روث من الماعز خلال الفترة من يناير ٢٠٠٦ إلى ديسمبر ٢٠٠٦. حيث بلغت نسبة الإصابة الكلية بالطفيليات المختلفة ٩١.٧%، بلغت نسبة الإصابة الكلية بالاياميريا ٨٨.٩%، بينما بلغت نسبة الإصابة الكلية بالديدان المختلفة ٢٥.٤%. كانت نسبة الإصابة الكلية للطفيليات فى الحيوانات الصغيرة (أقل من ٦ أشهر) ٩٧.٤% بينما كانت فى الحيوانات البالغة ٨٧.٣%. بلغت نسبة الإصابة بالديدان الاسطوانية ٢٢.٠%. وقد سجلت ديدان التريكوسترونجيليس أعلى نسبة إصابة بينها حيث بلغت ٦.٣% بينما سجلت ديدان الكابيلاريا أقل نسبة إصابة حيث بلغت ٠.٣%.

بلغت نسبة الإصابة بالديدان الشريطية (المونيزيا) ٢.٩%، وبالديدان المفلطحة ٣.٧% حيث كانت نسبة العدوى بالفاشيولا ٣.٤%، وبالبارمفستوم ٠.٩%. وبدراسة تأثير التغيرات الموسمية على نسبة الإصابة بالطفيليات المختلفة فى الماعز سجل فصل الصيف أعلى نسبة إصابة بالاياميريا حيث بلغت ٩٣.٨% بينما سجل فصلا الربيع والشتاء أعلى نسبة اصابة فى معظم الديدان.

ولتحديد أنواع الطفيليات الكبدية التي تصيب الماعز تم فحص ٣٥٠ من أكباد الماعز المذبوحة بقرى محافظة أسيوط. بلغت نسبة الإصابة الكلية بها ١٣.٧%، وحيث تم تشخيص كل من الفاشيولا والحويصلات القنفذية فى ٦.٣%، ٦.٨٦% من الحالات على التوالي، وذلك من خلال الفحص الظاهرى لأكباد الحيوانات المذبوحة. ومن خلال الفحص الباثولوجى تم لأول مرة فى محافظة أسيوط تشخيص الإصابة بكل من الاياميريا ويرقات الاسكارس فى أكباد الماعز فى ٠.٣% من الحيوانات. فقد وجدت أكياس الاياميريا فى محتويات القنوات الصفراوية. وأظهر الفحص الباثولوجى وجود الأطوار المختلفة للاياميريا فى أنسجة الكبد المصاب، وكان ذلك مصاحباً مع خلايا الالتهاب وزيادة فى النسيج الليفى فى المنطقة البابية والمجاورة للبابية مع وجود تغيرات تنكزية وتضخم وزيادة فى عدد الخلايا الطلائية للقنوات المرارية. أما فى حالة الإصابة بيرقات الاسكارس فقد وجدت اليرقات من خلال الهضم الاصطناعى لنسيج الكبد، كما وجدت قطاعات مختلفة لتلك اليرقات داخل الحبيبات الطفيلية فى أنسجة الكبد المصاب. وقد أتضح من النتائج أهمية الدور الذى تلعبه الماعز فى نقل الطفيليات لباقي الحيوانات خاصة إن معظم تلك الحيوانات كانت سليمة ظاهرياً، ولذلك ينصح بضرورة عمل فحص دورى لتلك الحيوانات للتأكد من خلوها من الطفيليات المختلفة.

