



THE POSSIBLE PROTECTIVE ROLE OF ANTIOXIDANTS (SELENIUM, VITAMIN E) IN REDUCING SMOKING EFFECTS ON TESTES OF ALBINO RATS

Binsawad A. Hanadi*, Abdul Hakeem M. Kelany*, Fatma M.
ElQudsi*, Hanan A. Ameen** and Salah A. El Karium*

*Dept. of Biological Sciences, Faculty of Science and **Dept. of Anatomy, Faculty of
Medicine, King Abdul-Aziz University P.O Box: 80205, Jeddah, 21589 KSA

ABSTRACT:

The main objective of the present work was to study the possible role of some antioxidant (Vitamin E "Vit. E" and Selenium "Se") in protecting the testicular tissue from degenerative changes evoked by exposure to cigarette smoking. The present work showed that exposure to cigarette smoking resulted in a significant decrease in body weight of animals where a significant increase of body weight was observed in animals supplemented with antioxidants while exposed to cigarette smoking. Animals given antioxidants alone did not show any differences in body weight compared to control groups.

Histological changes of testicular tissue of the group exposed to the smoke showed thickening of testicular capsule, widening of intertubular spaces with a decrease in interstitial tissue elements, vascular congestion, edema and thickened basement membrane of seminiferous tubules. Some of the seminiferous tubules showed distorted germinal epithelial cell layers, vacuolation and abnormal spermatids with ring shaped arrangement of peripheral chromatin. Giant multinucleated cells were also observed in some tubules. In some specimens there was an increase in the amount of degenerated tubules. Concerning the histochemical changes, the basal lamina, spermatids, Sertoli cells and interstitial tissue gave a very strong reaction with Schiff's reagent but spermatogonia given a weak reaction.

The present results showed that giving Vit. E and Se as antioxidant substances to cigarette smoking exposed animals, resulted in a decrease in the above histological and histochemical changes; the affected testicular tissues seemed to be more or less similar to controls. In conclusion, the present study showed that although using of certain antioxidants cannot completely prevent the drastic effects of cigarette smoking on living tissue, it prevented to some extent the degenerative changes observed in testicular tissues.

INTRODUCTION:

Tobacco smoke is a rich source of oxidants and reactive oxygen species. It has been argued that the increased production of reactive oxygen

species associated with smoking may exceed the capacity of the oxidant defense system, resulting in oxidative damage to selected proteins, lipids, and DNA (Winrow *et al.*, 1993). Cigarette smoke

is a complex mixture of more than 4000 different compounds that are inhaled with each breath while smoking. These constituents include many that are known to be pharmacologically active, toxic, mutagenic, and/or carcinogenic. Some of these agents are nicotine, tar, cadmium, carbon monoxide, carbon dioxide, cyanides, various hydrocarbons (Goodman and Gilman, 2001).

Chronic cigarette smoke inhalation is associated with an increase in the level of oxidants and a simultaneous decrease in the level of antioxidants in the Sprague-Dawley rat testis. This abnormality of the oxidant-antioxidant balance may be one of the mechanisms leading to testicular tissue damage (Rajpurkar *et al.*, 2000). Furthermore Koskinen *et al.* (2000) found that cigarette smoke induce acute changes in the testicular and cerebral microcirculation.

The deleterious effects of cigarette smoke on spermatogenesis in the testis of peripubertal Sprague- Dawley rats were demonstrated by Rajpurkar *et al.* (2002) and showed that cigarette smoking induces apoptosis in rat testis. A recent research showed that tobacco smoking in adulthood has a rather marginal impact on spermatogenesis and can hardly explain major shifts or regional differences in male reproductive health (Bonde and Storgaard, 2002). On the other hand researchers, including Pasqualotto *et al.* (2006), found that on the contrary cigarette smoking had no apparent effect on sperm concentration, motility or

reproductive hormonal levels, but tended to reduce semen volume in a population of fertile men. Hence the potential damage that can be caused by free radicals is normally minimized by a combination of biological antioxidant systems including enzymatic and non-enzymatic reactions (Kim *et al.* 2003).

Important antioxidants include copper and zinc and manganese superoxide dismutase, catalase, Selenium glutathione peroxidase (Se-GSH-Px), and glutathione reductase (GSH-Red). Ascorbic acid, α -tocopherol, and urate can also act to reduce the concentration of free radicals. As Selenium is well known as an essential micronutrient for animals and in order to determine whether its excess in diet induces morphological changes within the male reproductive system, therefore a detailed qualitative and quantitative evaluation of the changes in the histology of the testis and cauda epididymis was already undertaken in male rats (Kaur and Kaur, 2000).

Also, several studies have been carried out to find the mechanism of Selenium action through identified selenoproteins, especially selenoenzyme phospholipid glutathione peroxidase (PHGPx, GPx-4) which plays a pivotal role in regulating spermatogenesis. Moreover, the action of Selenium is best known as an antioxidant which acts through various selenoproteins viz. glutathione peroxidase, thioredoxin reductase and selenoprotein P (Shalini and Basal, 2005). Shalini and Bansal (2005) studied the role of Selenium in regulation of spermatogenesis, as Selenium (Se) is involved in the process of male reproduction.

Many workers have proved that Vitamin E is quite an effective antioxidant which protects rabbit testis against lipid peroxidation, where testosterone-induced lipid peroxidation could be improved by additional vitamin E treatment (Aydilek *et al.*, 2004). Furthermore vitamin E prevents nonylphenol-induced oxidative stress in testis of rats as reported by (Chitra and Mathur, 2004), but recently Beyrouthy and Chan (2006) found that co-consumption of Selenium and vitamin E altered the reproductive and developmental toxicity of methylmercury in rats.

Other workers have documented that vitamin E has protective effects on the testicular injury by cyclophosphamide in mice and they explained the possible mechanism of vitamin E to be its scavenging free radical and gonadotrophin released from the pituitary anterior lobe.

Although the association between the smoking habit and testes disease is universally accepted, but still little is known about the morphofunctional effects of smoking as directly manifested on the testes, Li *et al.* (2006).

Thus, the objective of this study was to assess the effect of cigarette smoking on structure of testes of the animals exposed to cigarette smoke and to recognize the possible prophylactic role of the antioxidants (Vitamin E "Vit. E" and Selenium "Se") in reducing the effect of cigarette smoking.

MATERIAL AND METHODS:

Drug and Chemicals:

1-Selenium was obtained from El-Gomhoria company in Egypt as Na_2SeO_3 , crushed and dissolved in distilled water (2mg/kg/BW in 2 ml of distilled water) (Francescato *et al.*, 2001).

2-Vitamin E was obtained from Bauiny company in Jeddah in dark glasses, kept at 2-8°C (100 mg/kg/BW in 2 ml of olive oil) (Weber *et al.*, 1997).

3- Golden leaf cigarettes each containing 10 mg of tar, 0.6 of nicotine and 12 mg of carbon monoxide were obtained.

Experimental animals:

The study comprised 40 Albino healthy adult rats each weighing 130-150 gm, were all selected and bred in king Fahad medical research center (KFMRC) at king Abdul-Aziz University. They were separated in plastic cages and fed the same balanced diet in addition to continuous supply of water for 2 weeks and left to acclimatize to the Laboratory temperature (ranging between 18-20±2°C) and relative humidity of (30%). A total of 40 animals were selected for the experiments and they received the chemicals by stomach tube.

Group 1 (Control group): 10 animals were selected and labeled as C group.

Group 2 (Antioxidant group): Another 10 animals were selected then divided into 2 subgroups labeled (A1, A2): each subgroup contained 5 rats, (A1) of this subgroup was supplemented with antioxidants (vitamin E dissolved in olive oil and Selenium dissolved in distilled water) for 3 weeks, and the other

subgroup (A2) continued to take the same dose for 5 weeks.

Group 3 (Smoking group): A third 10 animals were selected & divided into 2 subgroups labeled (SM1, SM2): the first subgroup (SM1), consisted of 5 rats, were exposed to cigarette smoke by inhalation for 3 weeks, the second subgroup (SM2), which also consisted of 5 rats, were exposed to cigarette smoke for 5 weeks.

Group 4 (Antioxidant–Smoking- Treated group): The last 10 animals were divided into 2 subgroups and labeled (SMA1, SMA2): the first subgroup (SMA1), consisted of 5 rats, were supplemented with antioxidants (Vit. E and Se) and smoke of cigarette for 3 weeks, but the second subgroup SMA2, consisted of 5 rats, were supplemented with antioxidants (Vit. E and Se) and cigarette smoke for 5 weeks.

The method used to evaluate the effects of both Vit. E and cigarette was proposed by (Simani *et al.*, 1974) and implemented by (Wang *et al.*, 2002) to expose the animals to cigarette smoke in a modified incubator. The rats were placed in a clear chamber connected to the smoking device and subjected to the cigarette smoke for 5 repeated times. Smoke puffs were drawn from a cigarette by vacuum and then blown inside the chamber. Smoke was released at the rate of 4 cigarette/15 minutes separated by 30 minute rest intervals for three times/day until the end of the study period (5 days/week). Animals were exposed to the smoke at the rate of 12 cigarettes per day each time. The control

rats were exposed to normal room air with the smoking machine in a similar fashion.

Histological study:

The external signs and mortality rate were recorded. During the different rest periods, the experimental animals were weighed, sacrificed, their testes were extracted, fixed in Bouin's solution, processed, and then paraffin-embedded. Sections were cut at 5 μ thickness stained with hematoxylin, eosin (H&E), Masson's trichrome as histological stains. However, Periodic acid Schiff (PAS) was used as a histochemical stain (Bancroft and Gamble, 2002). Histopathologic examination of the testes was carried out, and the testes were assessed quantitatively and qualitatively.

Morphometric Studies:

The Qwin 500 Ltd photo-analysis program was used to determine: (1) The mean thickness of tunica albuginea (MTT), (2) The mean seminiferous tubule diameter (MSTD), (3) The mean thickness of basal lamina of seminiferous tubule (MTBM). In the current test only round tubules were evaluated.

Statistical analysis and data presentation:

Data were presented as mean \pm standard deviation (M \pm SD).The statistical analysis was performed using analysis of variance (ANOVA) according to (Mould, 1989).

RESULTS:

Behavioral Observation:

When the rats were first exposed to cigarette smoke in the smoking chamber, they appeared excited and crowded in the corners of the cage, attempting to escape from the smoke. After inhalation of the cigarette smoke the rats had become more difficult to handle being more aggressive, frequently congregate, cluster to each other and started biting one another, although, this adverse response of the animals seemed to diminish gradually.

The present work showed that exposure of albino rats to cigarette smoke led to a significant decrease in body weight of animals compared to control $P=(<0.05)$ level of probability. A significant increase of body weight was also observed in animals supplemented with antioxidant while exposed to cigarette smoke $P=(<0.05)$ level of probability. Animals given antioxidant alone did not show differences in body weight compared to control (Table 1).

Histopathological Results:

Control group (C):

The specimens obtained from all animals of the control group were similar and revealed normal structural pattern of seminiferous tubular cells and interstitial cells of Leydig (Fig. 1, 11).

Anti-oxidant group (A1 & A2):

The specimens obtained from all animals of the antioxidant group revealed nearly normal structural pattern (Fig. 2, 12).

Smoking group (SM1 & SM2):

The histological alterations of the testes of rats exposed to cigarette smoke, started by apparent decrease in the interstitial tissue, followed by degeneration of some seminiferous tubules, which increased with prolongation of the exposure period.

After 3-weeks post-treatment, there were no detectable changes apart from an apparent increase in the inter-tubular spaces associated with decreased interstitial tissue.

By the end of the 5th week, the testicular coat of rats exposed to the cigarette smoke (Fig. 13) revealed thickening of their tunica albuginea and tunica vasculosa as compared to the control rats (Fig. 16). The germinal epithelium showed variable degrees of degeneration, and as a result of that the spermatogenic cells were reduced to few layers and the lumen of such tubules appeared to be wider as compared to the control group (Fig. 3). Further examination of the germinal epithelial cells, which were undergoing degeneration and necrosis, revealed obvious vacuolation of cytoplasm and nuclear changes, such as the loss of chromatin (karyolysis) and the other cells became smaller in size with darkly stained (pyknosis). There was a marked loss of these germ cells and a large vacuolar space had replaced the depleted cells (Fig. 4). In some tubules, spermatogenic cells stopped changing at various stages of spermatogenesis manifesting clear (hypoplasia). The most noticeable change was at the stage of primary spermatocytes (PS), spermatids (SD). However, the changed cells were fragmented and sloughed into the tubular lumina (Figs 4, 5). Also, there

was an apparent loss of germ cells and a large vacuolar space again replaced the depleted cells (partial depletion) (Fig. 6).

The degeneration of round spermatids often form multicellular aggregates with multiple nuclei included within a single mass of cytoplasm, these aggregates resembled abnormal multinucleated giant cells (Figs 7, 8).

The morphological changes of Sertoli cells in the examined sections post-exposure to cigarette smoke presumed to be degenerative and most appeared as generalized fine vacuolations in the basal cytoplasm (Fig. 9).

The interstitial tissue decreased around the tubules which was apparently normal or showing mild degenerative changes with reduced number of Leydig cells (Figs. 3-5, 9). On the other hand, the interstitial tissue was filled with homogenous eosinophilic ground substance in the region of damaged tubules and appeared less fibrous and more oedematous while nuclei of interstitial cells of Leydig were found to be more pyknotic (Figs 3-5, 9). The intertubular blood vessels appeared dilated and more congested (engorgement with large number of intact RBCs) (Figs 5, 9).

Antioxidant-smoking treated group (SMA1 & SMA2):

Our results showed that using certain antioxidant on rats exposed to cigarette smoke for 5 weeks was probably enough time for the testicular tissue to restore nearly its normal histological architecture. The cellular contents of the seminiferous tubules, germinal epithelium

and Sertoli cells, were all of normal shape and arrangement (Fig. 10). From Fig. 10 we noticed that, the cytoplasmic vacuolation of Sertoli cells were decreased, a noticeable increased in interstitial tissue with hypercellularity and a decreased congestion and dilatation of blood vessels. The basal lamina showed a slight thickening (Fig. 14).

Histochemical Results:

Control group (C):

The control rats showed intense PAS reactions in the basement membrane of the seminiferous tubules and spermatids, while a slightly weaker reaction was observed in the spermatogonia. The interstitial tissue showed intense reaction in the Leydig cells (Fig. 15).

Anti-oxidant group (A1 & A2):

This group showed the same distribution of PAS positive substance as those of the control group (Fig. 16).

Smoking group (SM1 & SM2):

The testes of rats exposed to cigarette smoke showed strong PAS reaction in the basement membrane, and interstitial cells. The spermatogonia showed weak reaction, while the interstitial tissue and dilated blood vessels showed very strong reaction (Fig. 17).

Antioxidant-smoking treated group (SMA1 & SMA2):

Our results showed that using antioxidant for rats exposed to cigarette smoke gave strong PAS reaction in the basement membrane,

Sertoli cells, spermatids and interstitial tissue while the reaction was weak in the spermatogonia (Fig. 18).

Morphometric Results:

In our study Vit. E and Selenium administration (group A1 & A2) showed no significant change in the Mean Seminiferous Tubular Diameter (MSTD), Mean Thickness of Tunica albuginea (MTT) and Mean Thickness of Seminiferous Basement Membrane (MTBM) compared with the control group.

As shown in Table 2, there was a significant increase $P=(<0.05)$ level of probability in the seminiferous tubule diameter in the rats

exposed to cigarette smoke for 5 weeks: 10.58μ versus 4.75μ in the control group animals. The tubule diameter has significantly increased $P=(<0.05)$ in the rats exposed to cigarette smoke and antioxidants for 5 weeks: 5.53μ versus 4.75μ in the control group animals. This difference was, statistically significant. In the smoking rats (group SM) (MSTD, MTT, MTBM) values were increased and this was statistically significant compared to the control groups.

On the other hand, rats exposed to cigarette smoke treated with Se and Vit. E showed a significant increase in (MSTD), decrease in (MTT, MTBM) as compared to the untreated smoking rats (Table 2).

Table (1): The mean body weight of experimental animals during the 5 weeks experimental duration

Weeks	Control rats (C)	Antioxidant (A1& A2)	Smoking (SM1 & SM2)	Smoking & antioxidant (SMA1 & SMA2)
1 st day	135.4±6.8	134.8±8.9	135.9±5.1	135.2±7.9
1 st week	146.2±12.9	145.3±7.9	131.6±6.0*	144.4±6.3
2 nd week	150.4±9.6	153.5±8.7	134.6±10.8*	147.8±5.8
3 rd week	154.2±9.9	156.3±8.8	144.2±10.3*	150.5±3.2
4 th week	161.0±9.5	160.2±9.1	149.2±11.5*	156.7±7.1#
5 th week	168.6±8.7	167.3±7.3	148.7±3.7*	163.3±5.2#

Values are represented as mean ± SD

P value at <0.05 level of significance

* Significant changes compared to control untreated (group I).

of significant changes compared to smoking untreated (group III)

Table (2): The statistical comparisons of the analyzed parameters in the testis of the studied group

Groups	MTT (μM)	MSTD (μM)	MTBM (μM)
Group 1 (C)	27.40±1.30	232.8±4.75	5.30±0.03
Group 2 (A1 & A2)	28.20±0.90	230.10±3.90	5.90±0.04
Group 3 (SM1 & SM2)	43.10±2.10*	197.00±10.58*	8.60±0.06*
Group 4 (SMA1 & SMA2)	36.50±0.80#	226.20±5.53#	6.10±0.03#

MTT: mean thickness of tunica albuginea.

MSTD: mean seminiferous tubular diameter

MTBM: mean thickness of seminiferous basement membrane.

Values are represented as mean \pm SD

P value at <0.05 level of significance

*** Significant changes compared to control untreated (group 1).**

of significant changes compared to smoking untreated (group 3).

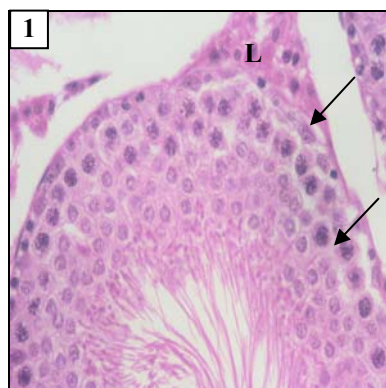


Fig. 1: A photomicrograph of a section in the testis of a control adult rat showing seminiferous tubule which contain Sertoli cells (arrow) and spermatogenic cells. The interstitial tissue contains Leydig cells (L), (H&E x400)

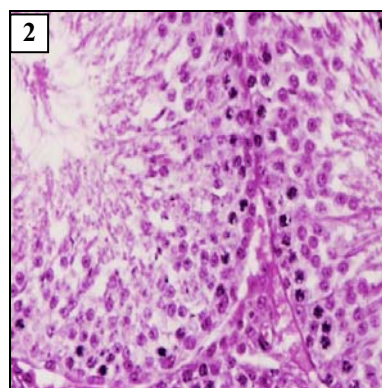
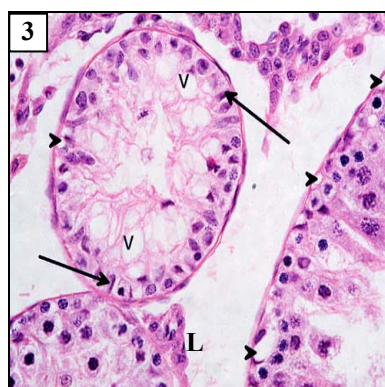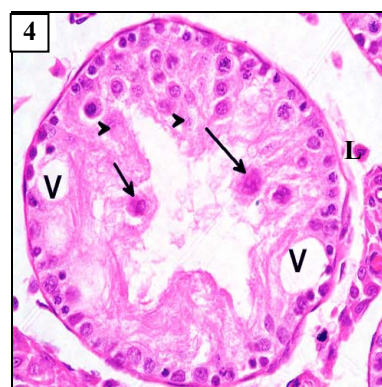


Fig. 2: A photomicrograph of a section in the testis of rat treated with antioxidant for 5 weeks showing nearly normal structure, (H&E x 400)

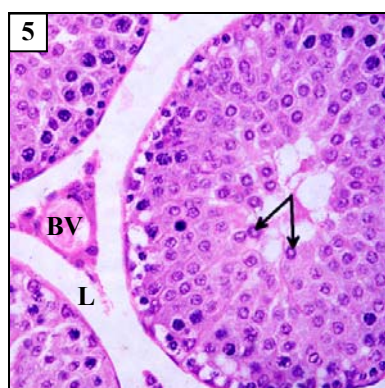
Figs. (3-6): A photomicrograph of sections in the testis of rat exposed to cigarette smoke for 5 weeks (H&E x400). Showing seminiferous tubule with:



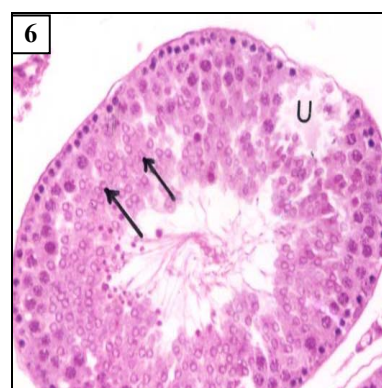
(3): Reduced layers of spermatogenic cells and many vacuoles (v), Leydig cells (L), vacuolated sertoli cells with flat dark nuclei (head-arrow), and nucleus dark and flat



(4): Large vacuoles (V), arrested spermatocyte (arrow) and necrotic cells (head-arrow), Leydig cells (L)

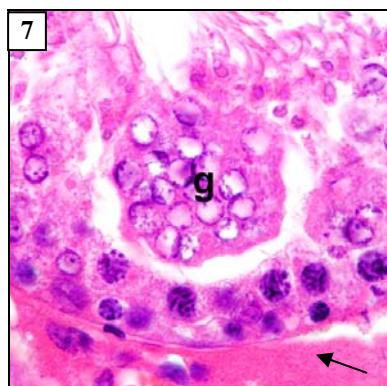


(5): Arrested spermatocyte (arrow) and dilated blood vessel (BV), Leydig cells (L)

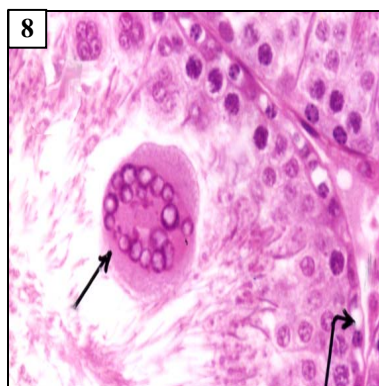


(6) Large vacuoles (partial depletion) (U), arrested spermatocyte (arrow)

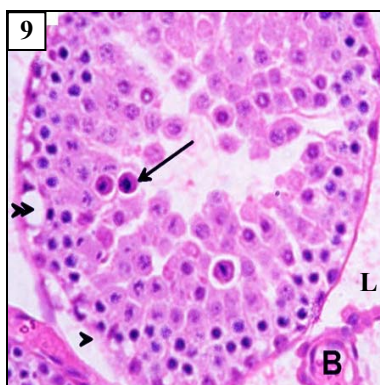
**Figs. (7-9): A photomicrograph of sections in the testis of a rat exposed to cigarette smoke for 5 weeks (H&E).
Showing seminiferous tubule with:**



(7): Abnormal multinucleated giant cell (g), diminished interstitial tissue with decrease in its cellularity filled with eosinophilic ground substance (arrow), Leydig cells (L) (H&E x1000)



(8): Abnormal multinucleated giant cell (straight -arrow) and basal vacuolation (curved-arrow), (H&E x1000)



(9): Spermatogenic arrest at spermatids stage (arrow), basal vacuole in Sertoli cell (double-head arrow) and shed off germinal epithelium (head-arrow). Due to decreased amount of interstitial tissue with congestion in the blood vessel (BV), (H&E x400)

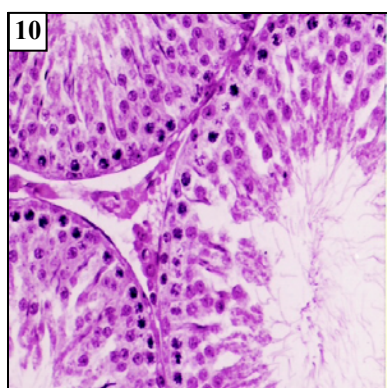


Fig. 10: A photomicrograph of a section in the testis of rat exposed to cigarette smoke plus antioxidant for 5 weeks, showing seminiferous tubule with normal shape and arrangement of cellular contents (H&E x400)

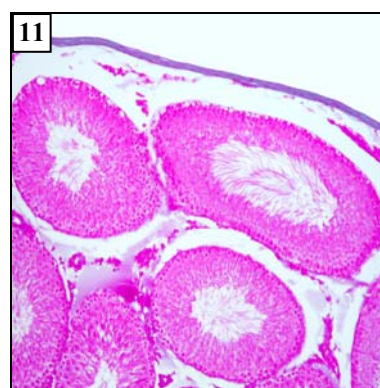

Fig. 11: A photomicrograph of a section in the testis of a control rat, showing thin covering capsule (Masson's trichrome x 100)

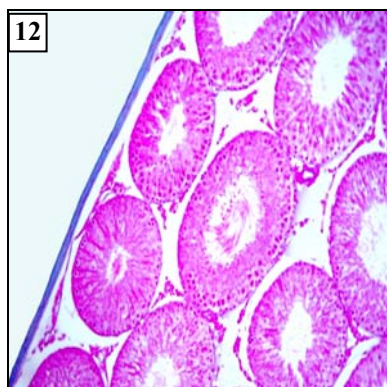


Fig. 12: A photomicrograph of a section in the testis of rat treated with antioxidant for 5 weeks, showing normal thickness of covering capsule (Massons trichrome x100)

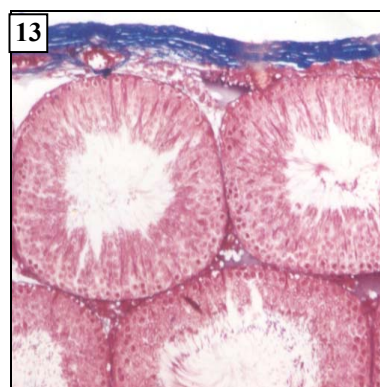


Fig. 13: A photomicrograph of a section in the testis of a rat exposed to cigarette smoke for 5 weeks, showing increased thickness of tunica albuginea and tunica vasculosa (Massons trichrome x 200)

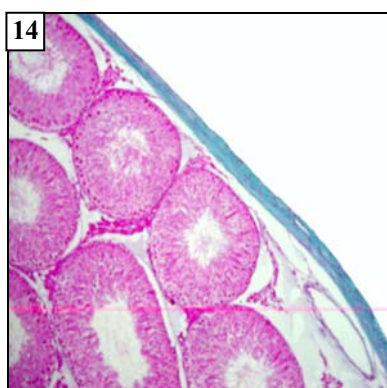

Fig. 14: A photomicrograph of a section in the testis of a rat exposed to cigarette smoke plus antioxidant for 5 weeks, showing normal thickening of basement membrane of the tubules and the covering capsule still thicker than in the normal group (Massons trichrome x100)

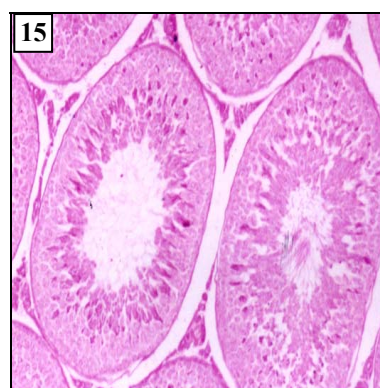


Fig. 15: A photomicrograph of a section in the testis of a control rat, showing strong PAS reaction in the basement membrane of the seminiferous tubules and spermatids, while a slightly weaker reaction was observed in the spermatogonia. The interstitial tissue showed intense reaction in the Leydig cells (PAS x200)

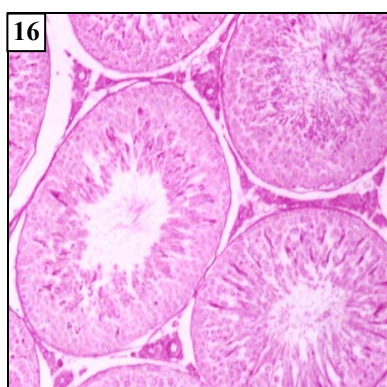

Fig. 16: A photomicrograph of a section in the testis of a rat treated with antioxidant for 5 weeks, showing the same distribution of PAS positive substance as those of the control group (PAS x200)

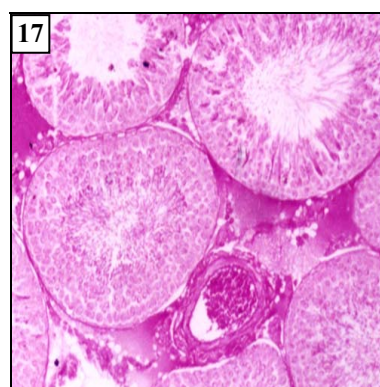

Fig. 17: A photomicrograph of a section in the testis of a rat exposed to cigarette smoke for 5 weeks, showing strong PAS reaction in the basement membrane, and interstitial cells. The spermatogonia showed weak reaction, while the interstitial tissue and dilated blood vessels showed very strong reaction (PAS x200)

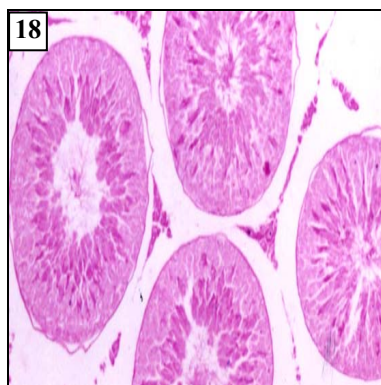


Fig. 18: A photomicrograph of a section in the testis of a rat exposed to cigarette smoke and antioxidant for 5 weeks, showing strong PAS reaction in the basement membrane, Sertoli cells, spermatides and interstitial tissue while the reaction was weak in the spermatogonia (PAS x 200)

DISCUSSION:

In this study, the pattern of decrease in body weight of the experimental animals, as recorded following the smoke exposure was similar to that recorded by (Li *et al.*, 2003 and Gentry-Nielsen *et al.*, 2004) and the apparent gain in weight post treatment with antioxidants (Selenium, Vitamin E). Our results agreed with (Beyrouthy and Chan, 2006), (Boitani and Puglisi, 2008) and (Chandra *et al.*, 2010).

The cause of the demonstrated decrease in weight might be related to a diminished food consumption caused by developed anorexia or decreased utilization of food (Gentry-Nielsen *et al.*, 2004) or may probably be due to the modification of protein metabolism, as greater proportion of the amino acids of the food protein was thought to be used for energy production rather than for growth and this metabolic modification appeared to be related to a considerable extent to the nicotine content of the smoke (Li *et al.*, 2003).

The present study showed that cigarette smoke caused a decrease in the interstitial tissue

with reduced number of Leydig cells, followed by degenerative changes in the germinal epithelium.

Our results were further strengthened by the work of Hassan *et al.*, 2007, who reported that a significant relationship exists between cigarette smoke and impaired testicular histology, which is also manifested as reduced diameter of seminiferous tubules and a decrease in the index of Sertoli cells in rats which is related to the reduction in sperm development process, however this can be generalized to human after careful histological studies.

Attia *et al.*, (1989) found that, spermatogenesis might be affected directly by nicotine or catecholamine released during smoking, as smoking in humans might affect the normal testicular steroidogenesis and spermatogenesis through adrenomedullary and adrenocortical hyperactivity as a result of induced stress.

In the present observations, the reduced number of spermatozoa and germ cells that were apparent with Leydig cell hypocellularity could support the observation of Raboch and

Mellen (1975) who reported a decrease in sperm density and motility in male smokers with significant incidence of deformed sperms (teratospermia) among men who smoked the most for longer periods of time, but attributed these effects to decreased testosterone levels.

We noticed that, the germ cells in the earlier stages of spermatogenesis (spermatogonia) were less affected by cigarette smoke than those in the later stages (spermatocyte and spermatids), this suggests that spermatogonia were more resistant to cigarette smoke toxicity. These observations supported the suggestion of Aydos *et al.*, (2001) that the spermatogonia were the most resistant germ cells in the seminiferous tubules.

The abnormal presence of cytoplasmic residual bodies shed by developing spermatids suggested an impaired capacity of Sertoli cells to ingest them (Güven *et al.*, 1999).

From the pathological reaction to cigarette smoke exposure, slight increase in the thickness of the tunica albuginea which might be due to active formation of fibrous tissue by the fibroblasts (Aydos *et al.*, 2001). Also, we found that the diameter of the seminiferous tubules in the experimental rats were decreased than the control group which agreed with that earlier stated by (Rajpurkar *et al.*, 2000).

Smoking might affect blood vessels through the release of vasodilator substances into the blood stream (Collin *et al.*, 1995). This dilatation of blood vessels was observed in the present work, especially in the intertubular blood vessels. This might result in slowing of the

testicular blood flow i.e. stagnation of blood in the testis and subsequently might in turn result in stagnant hypoxia to the testicular tissue.

Decreased germ cell number, differentiation and reduced fertility were observed at the altered Se levels earlier proved by the (Shalini and Bansal, 2005). After treatment with antioxidant, the regeneration of the entire germ cell population and recovery of functional spermatogenesis were nearly complete. Also, there were increases in the mean diameter of their seminiferous tubules and a decrease in the mean thickness of tunica albuginea when compared with the cigarette smoke group. These results were also in agreement with (Biotani and Pulgisi 2008), who proved that Se is essential for normal spermatogenesis of mammals and its critical role is mainly mediated by Selenoproteins viz (phospholipid hydroperoxide glutathione peroxidase and Selenoprotein P).

Rajpurkar *et al.*, (2000) found that usually smoke produced free radical of oxygen which causes oxidative damage in the testicular cells and Selenium had significant protective effects on testes of a rat against oxidative damage, in the presence of glutathione peroxidase (Kaur and Bansal, 2005). Furthermore, vitamin E has an antioxidant role against antipholinic oxidation to protect the testicular tissue (Aydilek *et al.*, 2004, Chitra and Mathur, 2004 and Chandra *et al.*, 2010).

A recently published work by Yue *et al.*, 2010, showed that the supplementation of Vit. E to Aohane fine-wool sheep gave a positive role in

improving semen quality via protecting testicular cell membrane and mitochondria from antioxidant abilities, however the optimal level of vitamin supplement should still be determined.

Also Vit. E supplementation was shown to increase weight of epididymis and the numeric density of convoluted seminiferous tubules reported by Hong *et al.*, 2009, which is in agreement with what we found in our work.

CONCLUSION:

The present study showed that chronic exposure to cigarette smoke resulted in drastic effects on the rats' testes, and using antioxidants cannot completely prevent these effects of cigarette smoking on living tissue, but it decreased to some extent the degenerative changes observed in testicular tissues.

REFERENCES:

- Ahmadnia, H.; Ghanbari, M.; Moradi, M.R. and Khaje-Dalouee, M. (2007): Effect of cigarette smoke on spermatogenesis in rats. *Urology Journal*, Vol 4, No. (3) 159-163.
- Attia, A. M.; El-Dakhly, M. R.; Halawa, F. A.; Ragab, N. F. and Mossa, M. M. (1989): Cigarette smoking and male reproduction. *Arch Androl.*; 23(1): 45-49.
- Aydilek, N.; Aksakal, M. and Karakilcik, A. Z. (2004): Effects of testosterone and vitamin E on the antioxidant system in rabbit testis. *Andrologia*. Oct.; 36(5):277-281.
- Aydos, K.; Guven, B.; Can, B. and Ergun, A. (2001): Nicotine toxicity to the ultra structure of the testis in rats. *BJU International*; 88: 622-626.
- Bancroft, J. D. and Gamble, M. (2002): The theory and practice of histological techniques. 5th edition. Churchill living stone.
- Beyrouthy, P. and Chan, H. M. (2006): Co-consumption of Selenium and vitamin E altered the reproductive and developmental toxicity of methylmercury in rats. *Neurotoxicol Teratol*. Jan-Feb.; 28 (1):49-58.
- Boitani, C. and Puglisi R. (2008): Selenium, a key element in spermatogenesis and male fertility. *Adv. Exp. Med. Biol.*; 636:65-73.
- Bonde, J. P. and Storgaard, L. (2002): How work-place conditions, environmental toxicants and lifestyle affect male reproductive function. *Int. J. Androl*. Oct.;25(5): 262-268.
- Chandra, A.K.; Chatterjee, A.; Ghosh, R. and Sarkkar, M. (2010): Vitamin E-supplementation protects chromium (VI)-induced spermatogenic and steroidogenic disorders in testicular tissue of rats. *Food Chem. Toxicol.*; 48 (3):972-9.
- Chitra, K. C. and Mathur, P. P. (2004): Vitamin E prevents nonylphenol-induced oxidative stress in testis of rats. *Indian J Exp Biol*. Feb; 42(2): 220-223.
- Collin, O.; Kilter, S. and Bergh, A. (1995): Tobacco smoke disrupts testicular

- microcirculation in the rat. *Int. J. Androl.*; 18(3): 141-145.
- Francescato, H. D.; Costa, R. S.; Rodrigues Camargo, S. M.; Zanetti, M. A. and Bianchi, M. D. (2001): Effect of oral Selenium administration on cisplatin-induced nephrotoxicity in rats. *Pharmacol Res. J.*; 43 (1): 77-82.
- Gentry-Nielsen, M. J.; Top, E. V.; Snitily, M. U.; Casey, C. A. and Preheim, L. C. (2004): A rat model to determine the biomedical consequences of concurrent ethanol ingestion and cigarette smoke exposure. *Alcohol Clin Exp Res.* Jul.; 28 (7): 1120- 1128.
- Goodman, A. G. and Gilman, S. L. (2001): The pharmacological basis of the therapeutics. MacMillan Publishing Co. Inc., New York, 10th edition.
- Guyen, M. C.; Can, B.; Ergun, A.; Saran, Y. and Aydos, K. (1999): Ultrastructural effects of Cigarette smoke on rat testis. *Eur Urol.*; 36 (6): 645-649.
- Hong, Z.; Hailing, L.; Hui, M. and Guijie, Z. (2009): Effect of vitamin E-supplementation on development of reproductive organs on Boer goat. *Anim. Reprod. Sci. Juli*, 113 (1-4): 93-101.
- Junqueira, L. C.; Carneiro, J. and Kelly, R. O.(1998): Basic histology. 8th edition. Prentice-Hall International, Inc. P.301-407.
- Kaur, P. and Bansal, M. P.(2005): Effect of Selenium-induced oxidative stress on the cell kinetics in testis and reproductive ability of male mice. *Nutrition.* Mar.; 21(3): 351-357.
- Kaur, R. and Kaur, K. (2000): Effects of dietary Selenium (SE) on morphology of testis and cauda epididymis in rats. *Indian J Physiol Pharmacol.* Jul.; 44(3): 265-272.
- Kim, S. H.; Kim, J. S.; S.; Shin, H. S. and Keen, C.L. (2003): Influence of smoking on markers of oxidative stress and serum mineral concentrations in teenage girls in korea. *Nutrition.*; 19: 240-243.
- Koskinen, L. O.; Coollin, O. and Bergh, A. (2000): Cigarette smoke and hypoxia induce acute changes in the testicular and cerebral microcirculation. *Ups J Med Sci.*; 105 (3): 215-226.
- Li, M. D.; Kane, J. K. and Konu, O. (2003): Nicotine, body weight and potential implications in the treatment of obesity. *Curr Top Med Chem.*; 3(8): 899-919.
- Mould, R. F. (1989): Introductory medical statistics. 2nd edition., Adam Hilger, Bristol and Philadelphia, pp. 17, 22, 126.
- Pasqualotto, F. F.; Sobreiro, B. P.; Hallak, J.; Pasqualotto, E. B. and Lucon, A. M. (2006): Cigarette smoking is related to a decrease in semen volume in a population of fertile men. *B J U Int.* Feb.;97(2): 324-326.
- Raboch, J. and Mellen, J. (1975): Smoking and Fertility. *Br. J. Sexual. Med.*; 2: 35-39.
- Rajpukar, A.; Dhabuwala, C. B.; Jiang, Y. and Li, H.(2000): Chronic cigarette smoking induces an oxidantantioxidant imbalance

- in the testis. *J. Environ Pathol Toxicol Oncol.*; 19(4): 369-373.
- Rajpurkar, A.; Jiang, Y.; Dhabuwala, C. B.; Dunbar, J. C. and Li, H. (2002): Cigarette smoking induces apoptosis in rat testis. *J. Environ Pathol Toxicol Oncol.*; 21(3): 243-248.
- Shalini, S. and Bansal, M. P. (2005): Role of Selenium in regulation of spermatogenesis: involvement of activator protein 1. *Biofactors.*; 23(3): 151-162.
- Simani, A. S.; Inoue, S. and Hogg, J. C. (1974): Penetration of the respiratory epithelium of guinea pigs following exposure to cigarette smoke. *Lab Invest.*; 31: 75-81
- Wang, D. F.; Qu, X. C. and Dai, Z. Q. (2002): Alteration of vitamin E levels in patients with pancreatic adenocarcinoma. *Di Yi Jun Yi Da Xue Xue Bao.* Mar.; 22(3): 210-211.
- Weber, P.; Bendich, A. and Machlin, L. (1997): Vitamin E and human health: Rationale for determining recommended intake levels. *Nutrition*; 13: 450-460.
- Winrow, V. R.; Winyard, P. G.; Morris, C. J. and Blake, D. R. (1993): Free radicals in inflammation: Second messengers and mediators of tissue destruction. *British Medical Bulletin*; 49 (3): 506-522.
- Yue, D.; Yan, L.; Luo, H.; Xu, X. and Jin, X. (2010): Effect of vitamin E-supplementation on semen quality and the testicular cell membranal and mitochondrial antioxidant abilities in Aohan fine-wool sheep. *Anim. Reprod. Sci.* 118 (2-4): 217-22.

الدور الوقائي المحتمل لمضادات الأكسدة (السيلينيوم و فيتامين هـ) في تقليل آثار التدخين على خصية الجرذان البيضاء

هندادي عبد الله بن سواد*، عبد الحكيم محمد كيلاني*، فاطمة محمد القدسي*،
حنان علي أمين**، صالح عبد العزيز الكريم*

*قسم علوم الأحياء - كلية العلوم ، ** قسم التشريح - كلية الطب

جامعة الملك عبد العزيز - المملكة العربية السعودية

الهدف من البحث دراسة الدور الوقائي المحتمل لبعض مضادات الأكسدة (فيتامين هـ، عنصر السيلينيوم)، وذلك لحماية أنسجة الخصية من الآثار المدمرة الناتجة من التعرض لدخان السجائر. استخدم للدراسة أربعون من ذكور الجرذان البيضاء البالغة، التي يبلغ متوسط أوزانها 130-150 جرام، حيث قسمت حيوانات التجارب إلى أربع مجموعات: المجموعة الضابطة، مجموعة مضادات الأكسدة "فيتامين هـ (100 ملجم/كجم) مذاباً في زيت الزيتون" و "السيلينيوم بصورة سيلينات الصوديوم (2 ملجم/كجم) مذاباً في الماء المقطر" بواسطة الأنبوبة المعدية عن طريق الفم، المجموعة الثالثة عرضت لدخان السجائر لمدة 3-5 أسابيع، أما المجموعة الرابعة تم إعطاؤها مضادات الأكسدة بنفس الجرعات السابقة أثناء فترة التعرض لدخان السجائر. تم تسجيل أوزان حيوانات التجارب أسبوعياً ثم قتلها عن طريق فصل الرأس عن الجسم بعد 3-5 أسابيع، ومن ثم تشريحها واستخراج الخصية لتحضير شرائح البرافين، وتم صبغها بالهيماتوكسيلين والأيوسين، صبغة ماسون ثلاثي الألوان، وكذلك طريقة حمض البيروديك كاشف شيف لدراستها نسيجياً وكمونسيجياً مع عمل دراسات قياسية.

أظهرت نتائج البحث أن التعرض لدخان السجائر أدى إلى انخفاض أوزان حيوانات التجارب بمقارنتها مع المجموعة الضابطة، بينما لوحظ زيادة في أوزان المجموعة التي أعطيت مضادات الأكسدة مع التعرض لدخان السجائر، أما الحيوانات التي أعطيت مضادات الأكسدة دون التعرض لدخان السجائر لم تحدث بها أي زيادة في الوزن مقارنة بالمجموعة الضابطة. وبالفحص النسيجي لأنسجة الخصية لوحظ زيادة في سمك المحفظة المحيطة بالخصية اتساع في المسافات بين الأنبيبات المنوية، نقص في كمية الأنسجة الضامة، تمدد واحتقان في الأوعية الدموية مع ارتشاح بلازمي وزيادة سمك الغشاء القاعدي للأنبيبات، اضطراب في طبقات الطلائية الجرثومية لبعض الأنبيبات المنوية، ظهور الفجوات في البعض الآخر، وجود طلائع منوية يظهر بها الكروماتين في وضع طرفي حلقي، ظهور الخلايا العملاقة متعددة الأنوية في بعض الأنبيبات المنوية وفي بعض العينات الأخرى لوحظ زيادة عدد الأنبيبات المنوية التالفة. أما التغيرات الكيمونسيجية والتي ظهرت في أنسجة الخصية المصبوغة بحمض البيروديك كاشف شيف هي شدة تفاعل الغشاء القاعدي للأنبيبات، الطلائع المنوية، خلايا سرتولي والنسيج البيني لهذا الحمض أما خلايا أمهات المنى تظهر تفاعل ضعيف وبالرغم من انخفاض كمية النسيج البيني في المجموعة المعرضة لدخان السجائر إلا أنه أظهر تفاعلاً شديداً لهذا الحمض.

وتشير الدراسة الحالية إلى أن إعطاء فيتامين هـ وعنصر السيلينيوم كمضادات للأكسدة لحيوانات التجارب التي تعرضت لدخان السجائر قد أدت إلى انخفاض التغيرات النسيجية والكيمونسيجية السابق ذكرها في أنسجة الخصية، والتي ظهرت بصورة قريبة مشابهة لمثيلاتها في المجموعة الضابطة. وأخيراً نستنتج من هذه الدراسة أن استخدام مضادات الأكسدة مع التعرض لدخان السجائر يؤدي إلى انخفاض الأضرار الناتجة عن التعرض لدخان السجائر، ولكنه لا يمنع كلياً التأثيرات الجانبية للتدخين.